

JMC College



St/ Joseph Convent



St/ Mary's College



ജി.ഐ.എ. റോഡ്

കോളേജ് റോഡ്

കോളേജ്

മേൽപ്പാലം
□ ട്രാൻസ്

□ മേൽപ്പാലം

മേൽപ്പാലം
□

കോളേജ് റോഡ്

കോളേജ്

കോളേജ് റോഡ്



കോളേജ് റോഡ്

Arpico



കോളേജ്



കോളേജ് റോഡ്

A. C. අවේනල්

f/111, අලුත් ගෙදර,
සියලුමාණ්ඩිය පාර,
කෑගල්ල.

2018.01.25

JMC ජාත්‍යන්තර පාසල,
කෑගල්ල,
විදුහල්පතිතුමනි,

අභ්‍යන්තර ප්‍රභාසු දිව්‍යාගේ අසන්න කණ්ඩායමේ ඉදිරිපස දැනුවත් කිරීම
සඳහා ඉදිරිපත් කරමි.

JMC ජාත්‍යන්තර පාසලේ පළමු ශ්‍රේණියේ ඉගෙනුම ලබන අභ්‍යන්තර
ප්‍රභාසු වන මාගේ දිව්‍යා කුමාර කුමාරී ජීව ආදර බෝගයෙන් හෙලෙන
අතර ඒ සඳහා සායනික ප්‍රතිකාර මගින් වරක් ලබා ගන්නා
බවත් වසරකට වරක් හදවතේ Echo පරීක්ෂණයකදී කරනු ලබයි.
ඒ සඳහාත් සායනික ප්‍රතිකාර ලබාගනී. තවද හෙබ්වර්ඩ් මහා විද්‍යාලයේ
දින දිව්‍යාට ගලපු කණ්ඩායමේ සිදුකිරීමටද නියමිතව තිබෙන අතර
ඉන් පසුව සති දෙකක අවසර කාලයකදී දිව්‍යා ජීවිතේ සුවිමට
සිදුවන බවත් මෙහි විදුහල්පතිතුමා වෙත දැනුවත් දෙමි. තවද අවශ්‍ය
සියලු තොරතුරු ඇතුළත් දිව්‍යාගේ සායනික වාර්තාව ජීවිතේ වෙස
න මාගේ අවසර ඇත.

මෙයට
මව
Senthya

4481/16

செலவு
சனாநாயம் } 48
Health
(8.5" x 9" இலக்கம்) 16/10

(ரோக விநிதலைய கார்டு/நோய் நிருணய அட்டை
Diagnosis Card)

ரீசீலே ஶார்ஸா ஶுமா ரோகல (கிணுண)
லேடி ரிஜ்வே சிறுவர் வைத்தியசாலை (போதனா)
Lady Ridgeway Hospital for Children (Teaching)

தூணதன ஶுணவ
தொ. போ. இல. } 011-2693711/4
Telephone No.

ஶத
பெயர் } Arosh
Name }
வயது } 47/12
Age }
ஶக்ரி பூரூஶ ஶாலைய } M
பால }
Sex }
ஶ.ஶ.ஶ. ஶுணவ } 36501/1
சட்டி. தலைப்பு இல. }
B.H.T. No. }

வாடா
வார்டு } VS-OPD
Ward }
ஶுணவ தூணதன } 16.06.2017
அணுணதூணதன தூணதன }
Date of Admission }
ஶிஜூ தூணதன } 16.06.2017
விடுவிக்கப்பட்ட தூணதன }
Date of Discharge }

ரோக விநிதலைய } R / Inguinal hernia.
நோய் }
Diagnosis }

ஶுணவ தூணதன ஶுணவ ஶுணவ } Repair of R Inguinal hernia.
ஶுணவ தூணதன ஶுணவ ஶுணவ } done under CIA by (VS)
Investigations and Treatment given }

ஶுணவ தூணதன ஶுணவ ஶுணவ } Mr. Ranjithu Ranawaka. Anstest Mr. Indrojan
Left lower transverse incision made. Inguinal
Canal open into. hernial sac identified &

ஶுணவ தூணதன ஶுணவ ஶுணவ } ligated & 4/10 cm. Skin sutured &
பரிந்துரைக்கப்பட்ட ஶுணவ தூணதன } 4/10 cm.
Treatment Advised }

ஶுணவ
தூணதன } 16.06.2017
Date }

2
ஶுணவ தூணதன ஶுணவ
விடுதி ஶுணவ தூணதன
House Officer

P
DR. A. R. S. RANAWAKA
ஶுணவ தூணதன ஶுணவ ஶுணவ
ஶுணவ தூணதன ஶுணவ ஶுணவ
பொது ஶுணவ தூணதன ஶுணவ ஶுணவ
Physician or Surgeon

ஶுணவ தூணதன ஶுணவ ஶுணவ ஶுணவ ஶுணவ ஶுணவ ஶுணவ ஶுணவ
ஶுணவ தூணதன ஶுணவ ஶுணவ ஶுணவ ஶுணவ ஶுணவ ஶுணவ ஶுணவ
ஶுணவ தூணதன ஶுணவ ஶுணவ ஶுணவ ஶுணவ ஶுணவ ஶுணவ ஶுணவ
ஶுணவ தூணதன ஶுணவ ஶுணவ ஶுணவ ஶுணவ ஶுணவ ஶுணவ ஶுணவ

Please show this Card whenever the Child is taken to a Doctor, Clinic or Hospital

7:30 am
ஶுணவ தூணதன / P.T.O.

RIV at VS OPD on 21/06/17

ID	6418
First Name:	Arosh
Surname/ Family Name:	
Age:	4 years, 4 months and 12 days

Hospital:	Lanka Hospital
Date of Echo:	23/03/2017 17:41:13
No:	24432

Echocardiography Report

Echo done by: Dr. Duminda Samarasinghe, Consultant Paediatric Cardiologist

Study type: Optimal with good windows

Situs loop, GAs: Situs solitus levocardia D loop normally related great arteries Concordant AV relationship Concordant VA relationship

Sys. ven. drainage: Normal systemic venous drainage

Pul. ven. drainage: Normal pulmonary venous drainage

Atria and IAS: Normal atria normal LA, normal RA, intact IAS.

AV valves: Normal AV valves normal Tricuspid valve, normal Mitral valve,

Ventricles: Normal ventricles, normal LV, normal RV, perimembranous VSD paritally patched up by STL, size: 2mm, left to right shunt, IVG: 78mmHg no RVOT obstruction, no LVOT obstruction,

Conotruncus: Normal pulmonary valve Normal aortic valve no aortic cusp prolapse or AR

Coronaries: Normal coronary origins

MPA, branch PAs: Normal MPA Confluent branch PAs

Aortic arch: Left aortic arch, no coarctation

Ductus Arteriosus: No PDA

Measurements:


Diagnosis: **Restrictive perimembranous VSD, no aortic cusp prolapse or AR**

Management: no need of cardiac intervention at the moment as the VSD is restrictive, no aortic cusp prolapse and there is a chance for spontaneous closure.
 * Can undergo GA with standard cardiovascular risk

Drugs: No need of cardiac medication

Other:

Plan: Review in 1year


DR. DUMINDA SAMARASINGHE



වෛද්‍යවරයා හමුවීමට මෙම කාඩ් පත රැගෙන යන්න.
வைத்தியரைச் சந்திக்கப் போகும்போது இந்த அட்டையை எடுத்துச் செல்லவும்.
Take this card when you visit the Doctor

නොමො 383a
சுகாதாரம் 383A
Health 383A
(Card* S.T. & E. 7 3/4" x 7 3/4")

රෝග නිශ්චය තුන්ඩුව
நோய் நிருணய அட்டை
DIAGNOSIS TICKET

රෝගියාගේ නම } Arash Divyanjana } වයස } 54 }
நோயாளியின் பெயர் } } வயது } }
Name of Patient } } Age } }
වාට්ටුව } 8B } ලේඛන අංකය } 72087 }
வார்டு } } பதிவு இல } }
Ward } } Reg. No. } }
ඇතුළු කළ දිනය } 5/11/2017 } 80 කළ දිනය } 7/11/2017 }
சேர்ந்த திகதி } } விடுவිத்த திகதி } }
Date of Admission } } Date of Discharge } }

රෝග පරීක්ෂාවන් හා ප්‍රතිකාර
பரிசீலனையும் சிகிச்சையும்
Investigations and Treatments

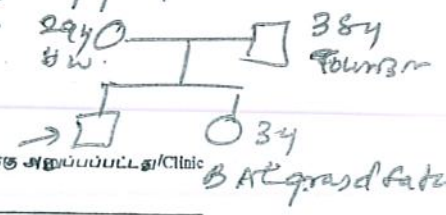
Acute exacerbation of BA

R/cough /
cold / 1 day

pmho - BA^T - on Asthelin
Salmeterol

R/B
Chesty cough PTV
Nasal congestion &
Nasal block
no fever
Sore throat +
no vomiting, ab. pain.
wsp
BO } NZ

PSHO - R/Inguinal hernia
Allergy - Not known.
Birth Mo - NVD - B.W - 2.5 kg
Im 1k - up to date.
A & D - age appropriate
Earls 4 - 2010



Referred to: විකිසාතාරයට යැවීම/கிளிசிகளுக்கு அனுப்பப்பட்டது/Clinic

ස. ආ. ව. ප්‍ර. පී. සෙ. වෛද්‍යවරයා/மரும வைய
சி. மரு. பி. மரு. ச மருத்துவ/அறுவை மருத்துவர் }
M. TU. WD. TH. FR. SA. Physician/Surgeon

ප්‍ර.ක. 8.00/ප්‍ර.ක. 2.00/8.00a.m/2.00 p.m. } Hospital / රෝහල
மு.ப. 8.00/ப.ப. 2.00 } மருத்துவ மனை

දිනය / திகதி Date: Dr Anuraatha (Ho)

(අතින් 80 බලනු)மறுபக்கம் பார்க்கவும்/பயிடுக
H 046239 - 5,000,000 (2015.08)P 3 ලංකා රජයේ ප්‍රයෝජනවත්
Kegalla.