

Neonatal Examination

TIFUWA

To be filled by the medical officer performing neonatal examination
 Date: 12/04/2020

Maturity of baby weeks

Baby's Growth SGA AGA LGA

Baby's blood gr

Component	Status		Component	Normal
	Normal	Abnormal		
Peripheries pink and warm			Scalp	
Hydrocyst			Mouth/lips	
Response to handling			Palate	
Capillary refilling time			Ears	
Pulse rate / volume			Abdomen	
Heart murmurs	Absent	Present	Umbilicus	
Femoral pulse			Groin	
Respiratory rate			Arms	
Groaning	Absent	Present	Hips	
Interosseal/subcostal recession	Absent	Present	Spine	
Tone			Limbs	
OPC			Dysmorphic features	Absent
Fontanelle suture line			Superficial infection abscess	Absent
Eyes / red reflex			Birth injuries	Absent

Any other abnormalities: None
 Action taken: eye to nose
 Transferred for special care Discharged

Diagnosis at discharge: Pre dental SPO
 Date of discharge: 12.5


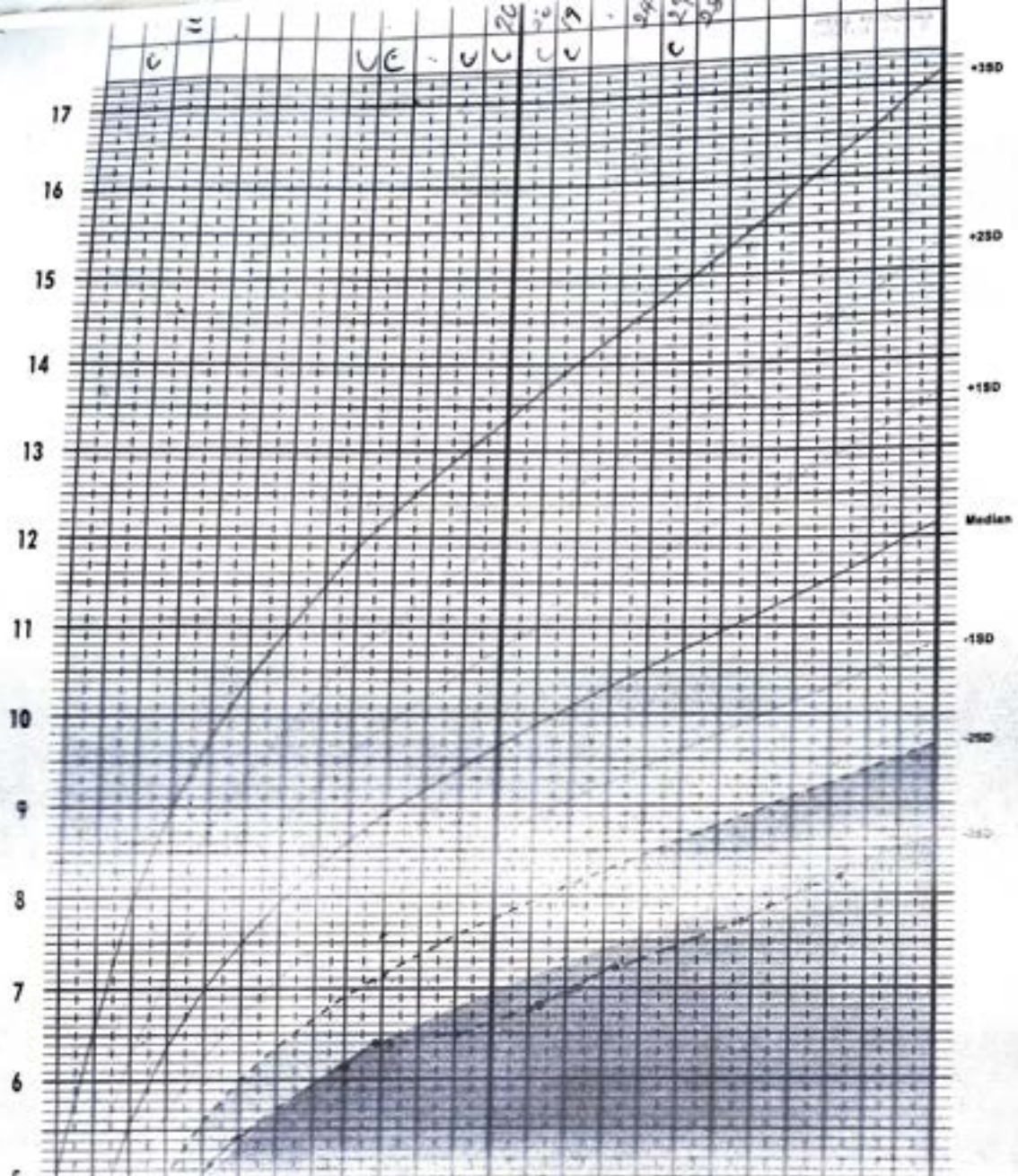
Other notes: Post dental SPO
 Pass Fail Refer

Weight	2.5 kg	Length	48 cm
Head circumference	34 cm	Temperature	37.5
Heart rate	120	Blood pressure	90/60
Respiratory rate	40	Saturation	98%
Reflexes	Present	Other	

Case No: 05.04.2020
 Date: 12/04/2020
 Time: 11:30 AM
 Age: 29 Y

Weight: 2.5 kg
 Length: 48 cm
 Head circumference: 34 cm
 Temperature: 37.5
 Heart rate: 120
 Respiratory rate: 40
 Reflexes: Present

Diagnosis: Pre dental SPO
 Date of discharge: 12.5



13	14	15	16	17	18	19	20	21	22	23	24
5-11	6-11	7-11	8-11	9-11	10-11	11-11	12-11	01-11	02-11	03-11	04-11

2 வகை ஏடுகள்
= 200 - 250

60 வகை நகர்ப்பகுதி பகுதிகள்

- (1-150) ஏறேன அகலம்
- (150-150) மெல்லிய வரம்பு
- (150-250) ஏறேன ஏறேன
- (150-350) ஏறேன ஏறேன
- (1-350) ஏறேன ஏறேன

Median

உயர் வகை
பிறந்த நகரம்

2020	04	11
------	----	----

உயர் வகை
பிறப்பு நகரம்

2020	320
------	-----